

LOCOMOTION AND MOVEMENT

① Types of Movement

- Amoeboid
- Ciliary
- Muscular.

1. Amoeboid movement : Exhibit by Macrophages and Leucocytes.

→ Effected by pseudopodia formed by streaming of protoplasm.

→ Microfilament also involved in amoeboid movement

2. Ciliary movement : Occur in internal tubular organ which are lined by ciliated epithelium.

→ Cilia in trachea help in removing dust particles and some of foreign substance inhaled alongwith air.

→ Passage of Ova through female reproductive tract facilitated by ciliary movement.

3. Muscular movement : Movement of limbs, jaw, tongue etc.

→ Contractile property of muscles used for locomotion and movement.

→ Required Coordinated activity of muscular skeletal and Neural System.

MUSCLE

→ tissue of mesodermal origin.
→ 40-50% of body weight

→ Special properties like excitability, contractility, extensibility and elasticity.

→ Classify using Criteria: Location, Appearance and nature of regulation.

→ Based on Location muscles are

(i) Skeletal (ii) Visceral (iii) Cardiac.

Skeletal Muscles: Associated with skeletal.
→ striped appearance. Hence also called striated muscle.

→ Activities are under the Voluntary Control of nervous system. Hence also known as Voluntary muscle.

→ Involved in locomotory actions and change of body postures.

Visceral Muscles: Located in inner wall of hollow visceral organ like alimentary canal.

→ smooth in appearance. Hence are called smooth muscles [non striated muscle].

→ Also known as involuntary muscle. Activities are not under Voluntary Control.

Cardiac muscles : Muscle of Heart.
→ striated
→ involuntary.

STRUCTURE OF MUSCLE FIBRES

- Made up of no. of Muscle bundles or Fascicles held together by E. Fascia [Connective tissue layer]
- Each fibre is lined by plasma membrane called sarcolemma enclosing the sarcoplasm.
- Muscle fibre is syncytium as sarcoplasm contains many nuclei.
- Sarcoplasmic reticulum is store house of Calcium ion.
- Presence of large number of parallelly arranged filament in sarcoplasm called Myofilaments or Myofibrils.
- Myofibril has alternate dark and light bands on it.
- Striated appearance is due to distribution of two ~~import~~ Important proteins - Actin and Myosin.

→ Light band contain actin and is called I-band or Isotropic band,

→ Dark band called 'A' or Anisotropic contain Myosin.

① Proteins are arranged as rod-like structure parallel to each other.

① Actin → thin → thin filament
Myosin → thick → thick filament.

① Centre of each 'I' band is an elastic fibre called Z line.

→ Thick filament in 'A' band held together in thin band by a thin fibrous membrane called M line.

① Position of two myofibril b/w two successive Z lines is called sarcomere
↓
functional unit of contraction.

① Central part of thick filament, not overlapped by thin filament is called H Zone.

* STRUCTURE OF CONTRACTILE PROTEINS.

Actin : Made of two 'F' [Filamentous] actins helically wound to each other.

→ F-actin is monomeric polymer of [Globular] 'G' actin.

→ Tropomyosin runs close to 'F' actin throughout its length.

→ Troponin distributed regular intervals on Tropomyosin.

→ In resting state a subunit of troponin mask the active binding site for myosin on actin filament.

Myosin : Monomeric polymer of protein Meromyosins.

→ Meromyosins have two parts.

Head with short arm

Tail

⊙ Called Heavy meromyosins [HMM]

Light meromyosin [LMM]

⊙ Project outward at regular distⁿ.

① Globular Head is an active ATPase enzyme and has binding site for ATP and active site for actin.

* MECHANISM OF MUSCLE CONTRACTION.

① Explain by Sliding Filament theory

↓
State that contraction of a muscle fibre take place by sliding of thin filaments over the thick filaments.

① Muscle contraction is initiated by signal sent by CNS.

① Motor neuron along with the muscle fibre connected to it constitute Motor Unit.

① Neuromuscular junction: Junction b/w motor neuron and sarcolemma of muscle fibre.

→ Neural signal reaching this junction releases a neurotransmitter [Acetyl Choline] which generate an action potential in sarcolemma.

→ Spread through muscle fibre and cause release of Calcium ion into sarcoplasm.



① Increase in Ca^{++} level lead binding with subunit of troponin on actin filament and remove the masking of active site for Myosin.

② Utilising the energy from **ATP hydrolysis**, myosin head binds to exposed active site on actin to form **Cross bridge**.

③ This pulls the attached actin filament towards the centre of 'A' band.

④ Z line attached to these actin pulled inward causing shortening of **sarcomere**.
i.e. **Contraction**.

⑤ During Contraction, the 'I' band get reduced where 'A' band retain the length.

⑥ Myosin releasing the ADP and P_i goes back to its **relaxed state**.

⑦ New ATP binds and Cross bridge is broken.

⑧ ATP again hydrolysed by myosin head cycle of Cross bridge formation and breakage is repeated causing sliding.





① Repeated activation of muscle lead to accumulation of lactic acid due to anaerobic breakdown of glycogen causing **Fatigue**.

② Muscle contain a red coloured **Oxygen** storing pigment called **Myoglobin**

③ Some muscle contain large no. of Myoglobin and give reddish appearance. and are called **Red fibres**

- Contain plenty of mitochondria which utilise large amount of Oxygen stored in them for **ATP Production**.
- also called **Aerobic muscles**

④ Some poses very less quantity of Myoglobin and appear pale or whitish and are called **White fibres**

- Mitochondria are few
- Amount of sarcoplasmic reticulum is high.
- Depend on anaerobic process for energy.

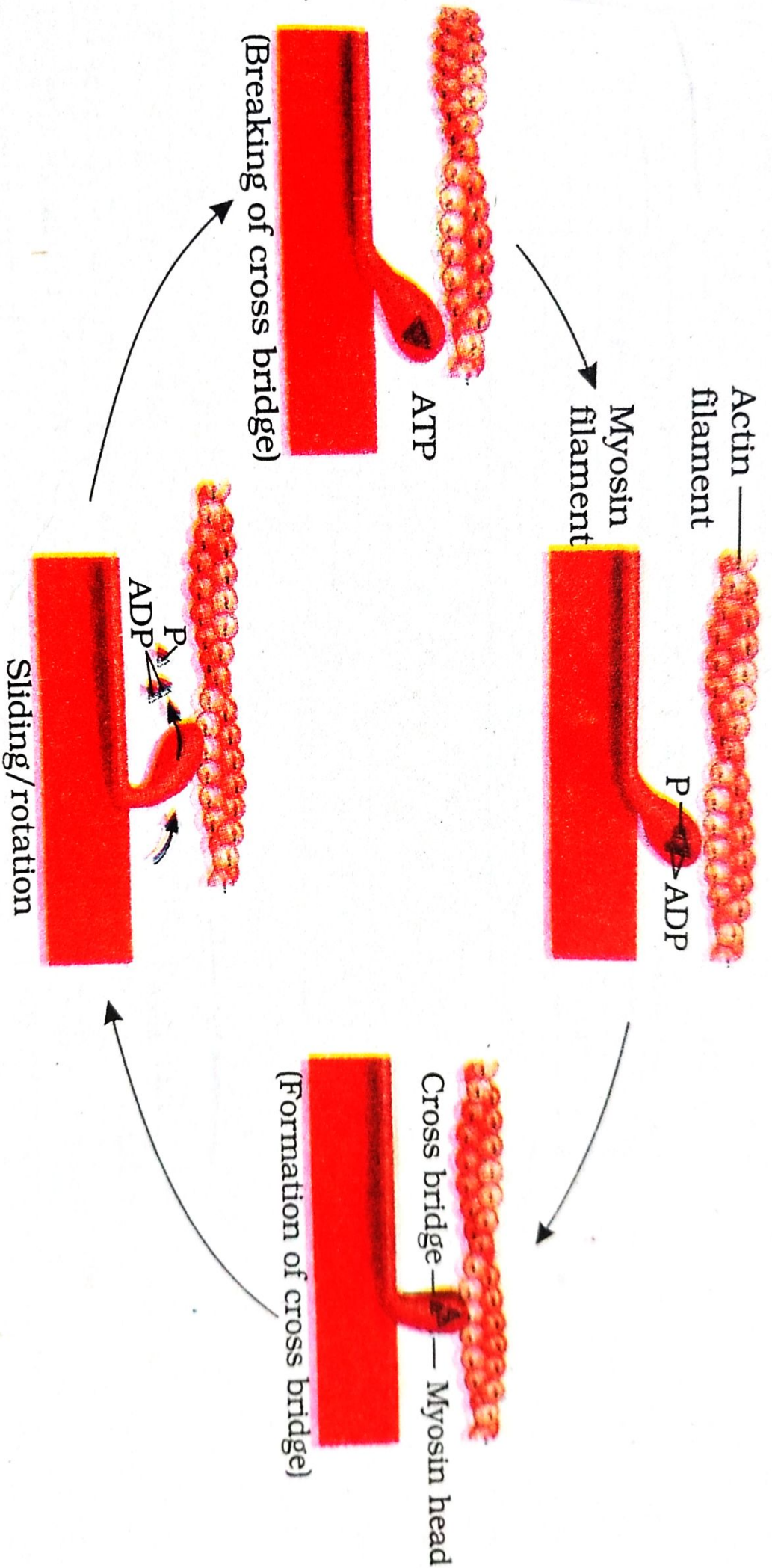


Figure 20.4 Stages in cross bridge formation, rotation of head and breaking of cross bridge



SKELETAL SYSTEM

→ Made up of 206 **Bones** and **Cartilages**.

↓	↓
Hard matrix Calcium salt	Pliable matrix Chondroitin salt

→ two principle Division

- (i) the Axial
- (ii) The appendicular.

AXIAL SKELETON

→ Comprises 80 bones.
→ Skull, Vertebral Column, Sternum and ribs constitute axial skeleton.

→ Skull → 22 bones divide into 2 sets.

(i) Cranial: 8 in Number and form hard protective Outer covering of brain, Cranium.

(ii) Facial region: Made up of 14 skeletal bones.
→ form front part of skull.

Hyoid: U shaped bone. Present at base of buccal cavity.
→ also include in skull.

Ear Ossicles: Skull region articulates with Middle ear. Contain 3 bones - Malleus, Incus, Stapes.

① Skull region articulates with superior region of vertebral column with the help of two occipital condyles.

→ Vertebral Column: formed by 26 serially arranged units called **vertebrae** and is dorsally placed.

① Has central hollow portion [**neural canal**] through which spinal cord passes.

① **Atlas**: First vertebra and articulates with occipital condyles.

① Differentiated into **Cervical** [7], **thoracic** [12], **Lumbar** [5], **Sacral** [1-fused] and **Coccygeal** [1-fused]. Regions starting from skull.

① Protect spinal cord, support head and serves as point of attachment for ribs.

① **Sternum**: Flat bone on ventral midline of thorax.

① Ribs : 12 pairs and Connected dorsally to the Vertebral Column and Ventrally to sternum. with the help of **hyaline Cartilage**.

→ Has two articulation surface ~~is~~ and is called **bicephalic**.

→ first seven pairs are called true ribs.

→ 8th, 9th and 10th are called **Vertebrochondral** [false ribs].

→ Last 2 pairs are called **Floating ribs**.

* Appendicular Skeleton

① ~~Constitute~~ Consist limbs alongwith girdles.

① Each limb is made of 30 bones.

1. Forelimbs : Bones are Humerus, radius and Ulna.

① Carpals [wrist bone - 8], Metacarpals [palm bone - 5], phalanges [digit - 14]

2. Hind limbs : Femur [thigh bone - longest bone] tibia and fibula.

① Tarsals [ankle bone - 7]; Metatarsals [5] and phalanges [Digit - 14].

① Pectoral and Pelvic girdle bones help in articulation of upper and lower limbs respectively with axial skeleton.

② Each girdle form two halves. Each halves of pectoral girdle consist of clavicle and scapula.

③ Scapula is large triangular flat bone situated in dorsal part of thorax b/w second and seventh rib.

④ Dorsal, flat, triangular body of scapula has a slightly elevated ridge called **Spine** project as flat, expanded process called **Acromion**.

⑤ Below acromion is a depression called **glenoid cavity** → articulate with head of humerus to form shoulder ~~joint~~ joints.

⑥ Clavicle is long slender bone with two curvatures. This bone commonly called **Collar bone**.

○ Pelvic girdle consist of two Coaxal bone

→ Coaxal bone is formed by fusion of three bone - ilium, ischium and pubis.

→ ~~formed by~~ fusion of above bone is a cavity called **Acetabulum** to which thigh bone articulates.

JOINTS

○ Joints are point of contact b/w bone and Cartilages or b/w bones.

→ Classified into three major structural form

1. Fibrous joint : Do not allow movement.

→ shown by Flat skull bone which fuse end to end with the help of dense ~~fibro~~ fibrous connective tissue.

2. Cartilaginous joints : permit limited movement.

→ Bones joint together with the help of Cartilages.

→ eg: joint b/w adjacent Vertebrae



3. Synovial joints : Help in locomotion and other movement.

→ Characterised by presence of fluid filled **Synovial Cavity**.

eg: Ball and socket joint [b/w humerus and pectoral girdle].
Hinge joint [knee joint].

DISORDERS OF MUSKULAR AND SKELETON

* **Myasthenia Gravis** : Auto immune disorder
→ affect Neuro-muscular junction.
too leading to fatigue and paralysis.

* **Muscular dystrophy** : Progressive Degeneration of skeletal muscle.

* **Tetany** : wild contraction in muscle due to low Ca^{++} in body fluid.

* **Arthritis** : Inflammation of joints.

* **Osteoporosis** : Age related disorders

→ decreased bone mass and increased chance of fracture.

* **Gout** : Inflammation of joint due to accumulation of uric acid crystals.